

**PAPER****ODONTOLOGY**

*John W. Berketa,<sup>1</sup> B.D.S.; Robert S. Hirsch,<sup>1</sup> B.D.S., M.D.S., Ph.D.; Denice Higgins,<sup>1</sup> B.D.S.; and Helen James,<sup>1</sup> B.D.S.*

## Radiographic Recognition of Dental Implants as an Aid to Identifying the Deceased

**ABSTRACT:** This study was undertaken to determine if dental implants can be radiographically differentiated by company type to aid forensic identification of the deceased. Recognition of dental implants on intraoral radiographic images was assessed in a blind study using a radiographic examination guide to highlight differences between dental implants. Inter- and intra-examiner comparisons were conducted and a computer program (Implant Recognition System<sup>®</sup>) was evaluated to see whether it improved the accuracy of implant recognition. The study found that dental implants could be radiographically differentiated by company type. The Implant Recognition System<sup>®</sup> in its current form was of little benefit for radiographic assessment of dental implants for forensic odontologists. Prior knowledge of implant types, with a McNemar's statistical value of 92.9, proved to be most significant in identification.

**KEYWORDS:** forensic science, forensic odontology, human identification, dental radiography, dental implants, Implant Recognition System<sup>®</sup>

The formal identification of a deceased person relies on evidence. Dental identification of the deceased involves the methodical approach of matching data from a postmortem examination to antemortem dental data in a given name (1,2). In cases of single and multiple deaths, scientific identification utilizing forensic odontology is often the major source of identification (3–7).

The increasing use of dental implants as a viable dental treatment option will increase the frequency of implants becoming a part and, in some circumstances, most of the recorded antemortem information for an individual. A victim's dentition could be totally constructed from implants with no natural dentition remaining. Implants are known to resist mechanical and thermal insult (8,9). In cases of severe incineration, implant bodies and abutments may be the only dental remains as titanium implants have a high melting point (>1600°C) (10).

In dental practice, imaging is recommended for preoperative evaluation of the implant site, postoperatively for the evaluation of correct seating of the abutment and further evaluation of bone loss under an implant maintenance regime. The postmortem detection of an implant would signal the likelihood that radiographs were taken by a treating dentist and may be located with other antemortem data. However, care should be exercised when using dental treatment radiographs for direct comparison against postmortem radiographs as there are distortion and angulation factors that need to be considered.

Currently an implant detected in a postmortem radiographic examination is likely to be charted simply as an implant, with little further information. Greater weight to an opinion regarding identification of the victim could occur if the name of the manufacturing company, type, width, or length of the dental implant(s) could be accurately determined and recorded.

<sup>1</sup>School of Dentistry, University of Adelaide, Adelaide, SA 5005, Australia.

Received 5 Aug. 2008; and in revised form 23 Dec. 2008; accepted 4 Jan. 2009.

The options for identifying the details of implant bodies in the deceased include intraoral examination, intraoral radiography, three-dimensional imaging, for example using a CT scanner, panoramic radiography, physical removal of the implants for direct measurement and visual analysis. In jurisdictions where there are legal or cultural barriers to resection of implants, intraoral radiography would be the method of choice for most odontologists. Intra-oral radiography of implant bodies has many advantages, especially as it is already in common use by odontologists in postmortem examinations. It is inexpensive in comparison to three-dimensional and panoramic imaging and is more readily usable on a prone body. In a large disaster victim identification scenario where a temporary mortuary has been established, the use of portable radiographic machines will allow intra-oral radiographic imaging (11).

The main disadvantage of intra-oral radiography as a diagnostic tool in the identification of implants is projection geometry causing distortion and magnification of the image. Variations in image size are greatest when the bisecting angle technique is used compared to the long cone paralleling technique (12,13) although even this technique does not guarantee the correct image size. To minimize distortion, the periapical film or a digital sensor needs to be positioned close to the dental structures and at right angle to the X-ray beam using a rigid commercial film or sensor holder.

### *Implant Recognition Using Radiographs*

In 1992 Sewerin (14) identified the influence of various features of implants, (threads, cuts, holes, perforations, and flutes) on the radiographic image produced. In another study by Sahiwal (15) the coronal, midbody, and apical thirds of implants were categorized. The coronal features included the prosthetic interfaces of external hex, internal hex, morse taper, and "other" such as the spline interface. The features of the midbody of an implant were tapered, non-tapered, threaded, V-shaped threads, square threads, reverse buttress

threads, grooves, and any “other” unique features. The features of the apical third of an implant included V-shaped apex, flat apex, curved apex, round hole, oblong hole, apical chamber, grooves, and any “other” unique features (15).

In 2006 Michelinakis et al. (16) developed computer software to assist in the identification of implants *in vivo* using a range of queries in regard to the implant image. A database was compiled of 87 implant manufacturers listing the characteristics of their implants. Most dental implant systems have several widths as well as four or five lengths. Other characteristics included in the database were shape, surface, presence of threads and differences in the coronal section. The software program (Implant Recognition System® [IRS®]) queries the known features of the implant through a series of drop-down boxes which prompt the user to enter information about implants under the headings: implant type, implant description, threaded, surface, collar, diameter, and length. Initiating the program’s search function reveals a list of possible implants with the manufacturer and implant name.

A more localized geographic data approach would simplify recognition decreasing the sheer numbers of implants involved. However, the IRS® has attempted to maintain a multinational matrix rather than a more focused national approach reflecting the ease and popularity of international travel.

The aim of this study was to assess whether dental implant type could be identified from radiographs and if the IRS® improved the accuracy of recognition.

## Materials and Methods

Ethical approval from the University of Adelaide Human Research Ethics Committee (no. H-069-2007) was obtained. A


















Features	Options				
Shape	Cylindrical 	Disc 	Blade 	Subperiosteal 	
Thread		Thread 	Non-thread 		
Taper		Tapered 	Straight 		
Flange	Wide 	Straight 	Flared 	Reverse Flared 	
Apex	Grooved 	Hole 	Flat 	Curved 	Pointed 

FIG. 1—Identification guide to the classification of implants.

request via email was sent to forensic odontologists both nationally and internationally and to local dentists requesting radiographic images of dental implants. The criterion for inclusion of an image in the study was that the body of the implant was totally depicted. The implant type and other details were forwarded with the image directly to a colleague not involved with the identifications. If radiographic films were received, they were digitized using a Nikon™ 2000 camera (Tokyo, Japan). The images were tabulated according to their country of origin, name of image provider, type of radiograph, location within the mouth (if known) together with the implant type. A total of 200 radiographic images were then de-identified for a blind study and randomly coded for reference before independent viewing by examiners of which two were only available at that time. Implant identification by the examiners was standardized and guided by reference to a grid of implant characteristics (Fig. 1).

To test inter-examiner differences, both examiners assessed and recorded the 200 images in the same order. To test intra-examiner error, the implant images were re-examined by the same examiner but in a different random order 1 week later. The IRS® system was then used to evaluate its usefulness in the implant identification process; both examiners examined all the images utilizing the IRS® and repeated the process a week later with the images in a different random order.

As the testing samples (images) were of the same data, the McNemar’s test was used to test for significant differences between the rate of correct identification within examiner, across examiner, and across IRS® status within each examiner. The McNemar’s test is applied to tables with a dichotomous trait. Significance was set at 95%.

## Results

The number of correctly identified implants from a total of 200 radiographic images at each examination is shown in Table 1. Examiner 1 was more successful at identifying implant type than Examiner 2 at each assessment. Use of the IRS® produced a higher combined total of correct identifications (in the first and second trials) for each examiner, although Examiner 2 achieved the same total in the second assessment with and without the IRS®.

Table 2 shows the results of the McNemar’s tests and the conclusions on significance. The use of the IRS® or not is depicted as + or –IRS®. The numerical value is shown below McNemar’s statistic heading and the degree of freedom for each test is 1.

Tests numbered 1 to 4 showed no significant difference between the first and second trials of each examiner with or without the IRS®. Tests numbered 5, 6, and 7 related to the use of the IRS® and to its significance. Examiner 1 had a significant statistical improvement in test 5, whilst Examiner 2 did not show a significant statistical improvement in test 6. Combining both examiners results showed a significant statistical improvement in test 7.

Tests numbered 8, 9, and 10 related to the differences between the examiners recognition rate. All three tests (without the IRS® in

TABLE 1—Summary of the number of correct implant identification radiographic images at each assessment.

	Examiner 1	Examiner 2
First assessment without IRS	111 (55.5%)	77 (38.5%)
Second assessment without IRS	119 (59.5%)	80 (40%)
First assessment with IRS	131 (65.5%)	86 (43%)
Second assessment with IRS	123 (61.5%)	80 (40%)

TABLE 2—McNemar's tests results.

Test No.	Test	McNemar's Statistic	Freedom	Pr > S	Significance
1	Examiner 1 –IRS 1st vs. 2nd	2.0	1	0.16	No
2	Examiner 1 +IRS 1st vs. 2nd	3.6	1	0.06	No
3	Examiner 2 –IRS 1st vs. 2nd	0.2	1	0.64	No
4	Examiner 2 +IRS 1st vs. 2nd	1.1	1	0.30	No
5	Examiner 1 –IRS vs. +IRS	10.6	1	<0.0011	Yes
6	Examiner 2 –IRS vs. +IRS	1.2	1	0.27	No
7	Total –IRS vs. +IRS	9.0	1	<0.0027	Yes
8	–IRS	36.25	1	<0.0001	Yes
9	Examiner 1 vs. Examiner 2 +IRS	58.7	1	<0.0001	Yes
10	Examiner 1 vs. Examiner 2 Total	92.9	1	<0.0001	Yes

test 8, with the IRS<sup>®</sup> in test 9, combining with and without IRS<sup>®</sup> in test 10) showed a strong numerical significant difference.

## Discussion

The sample of 200 implant images used in this study was provided by dentists and odontologists from 12 different countries, which gave a broad sample base of implant images. There were 22 different implant manufacturers represented in the sample. The most common implant manufacturers were Nobel-Biocare<sup>™</sup> (Zurich, Switzerland), Straumann<sup>™</sup> (Waldenburg, Switzerland) and Branemark<sup>™</sup> (Gotenburg, Sweden) reflecting the popularity of these implants (17). If the examiners were more familiar with these popular implants this overrepresentation could bias toward increased correct identifications. Future studies might include more variety of dental implant images.

In this study, if the examiner was unable to identify an implant, then a guess was made based on the examiner's prior knowledge of implants. An incorrect identification, where the physical characteristics were misinterpreted, carried the same weight as a nonidentifiable implant (where the quality of the image precluded identification or that the examiner had no knowledge of that type of implant). In future studies the distinction between incorrect identifications and nonidentifiable implant image should be made.

Differentiation between intraoral and extraoral radiographs was not considered in this project and further research could be conducted to compare the attributes, when examining dental implants, of the different forms of radiography available.

As the 200 images were assessed in a single day, the human factors of visual tiredness, Mache effect (18), distractions, and boredom might have influenced the outcome, although this would be extremely difficult to measure. Spacing the assessments over a longer time frame might have reduced some of these sources of error.

## Intra-Examiner Differences

There was no significant difference between the first and second trials of both examiners with or without the IRS<sup>®</sup>.

## Inter-Examiner Differences

Inter-examiner error was a significant factor in this study. There was a significant difference between the success rates of one examiner compared to the other (46.7%). This would suggest that the assessment was influenced by each examiner's baseline knowledge of implants, whether they had previously obtained knowledge of a specific company's implant being assessed and which companies' implant products they had recently reviewed.

The interpretation of each implant characteristic by the examiners differed in many cases, with the flange assessment producing the greatest variability. The flange images were problematic due to the subtleties of the different flares and also depended on the quality of the radiographs in detecting these subtleties. The exceptions were the non-TE Straumann<sup>™</sup> which has a distinct flare and the Biocon<sup>™</sup> (Bangalore, India) that has a reverse flare.

Poor angulation, lack of clarity, and poor definition of some images made the visual assessment of threads, heads, and grooves difficult in some cases. This highlighted the need for more detailed definition of the criteria together with good quality radiographs to assess images to achieve an improved accuracy in identification.

The implant bases were the most useful feature in implant identification; even the poorest image provided helpful information. The grooves within the apical third of some implants also aided in identifying implant types. As seen in Fig. 2, the groove pattern has subtle but noticeable differences between Branemark<sup>™</sup> III and IV, 3i<sup>™</sup> (London, U.K.), Zimmer<sup>™</sup> Twist (Warsaw, IN) and Astra<sup>™</sup> (Westborough, MA).

## Implant Recognition System<sup>®</sup> (IRS<sup>®</sup>)

The combined success rate of both examiners without the IRS<sup>®</sup> was 48.4%. Adding the utilization of the IRS<sup>®</sup>, the success rate increased only marginally to 51.3%. Both rates of successful recognition are poor for forensic identification casework. For the IRS<sup>®</sup> to become an effective tool for identification purposes in assessing radiographs more radiographic images are required in its database. Currently the IRS<sup>®</sup> has only 18 radiographic images of 13 different types of implants of a total of 234 implant types in the database.

A further handicap was that 11 of the companies from a total of 23 represented in the study sample were not included in the current IRS<sup>®</sup> database. The IRS<sup>®</sup> is currently being updated to increase the number of implant manufacturers and implant types. This will be an ongoing problem as new implants are designed to improve their success rate and any database will need to be constantly updated. If the IRS<sup>®</sup> included information regarding grooves and holes and descriptions of the end of the apex, more differentiation might be attainable. Internet access to the IRS<sup>®</sup> with a constantly updated database would increase access all over the world; its creators have formed a website with that in mind (19).

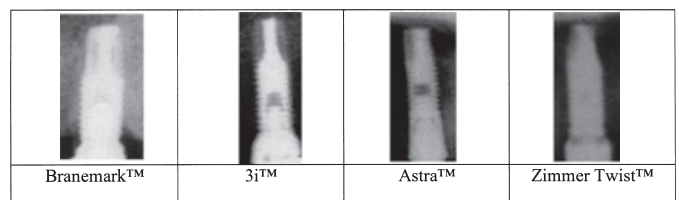


FIG. 2—Images of the groove pattern of flat-ended implants.

### *Recommendations for Odontologists Regarding Implant Identification*

This study has highlighted the difficulty in identifying dental implant type from nonstandardized radiographs. The IRS<sup>®</sup> in its current form did not provide sufficient information for the correct identification of dental implant types from radiographic images in many cases. A suggestion would be to include at least one good clinical radiographic image of each implant in the database.

Wherever possible, radiographs should be taken with the beam of the X-rays at right angle to the long axis of the implant and film so that distortion and enlargement is minimized. The total implant should be visible as the apex and the head of the implant provide the most important differentiating features. A second image taken at approximately 30° rotation to the long axis of the implant from the first radiograph might also help clarify the pattern of the grooves and holes.

The guide to radiographic implant identification produced in Fig. 1 could be enhanced to include more detailed information in relation to the bases of implants and further features currently being developed, such as Zirconian implants. Many companies are incorporating the successful features of other companies' implants into their own designs. The trend of the latest implants of becoming tapered, threaded, roughened surface curved apexes but without holes will make differentiating between company types even more difficult in the future. A quantum leap in design may lead to the current design concepts being obsolete, as has happened with machined surfaced implants. A database which included the dates of manufacture of particular implant types would also assist in age estimation of a deceased person, providing further clues to the person's profile.

It might be beneficial to include a radiopaque object of known size, for example a 5mm stainless steel ball (Sirona<sup>™</sup> Ref. 6034321 D3352), on the occlusal surface on the implant or if the crown is still present, measure the width of the crown and irradiate both the implant and crown/ball. If the image was produced digitally then the software of the digital company can calibrate the image, but if a conventional film was used the film could be either digitally photographed or scanned and calibrated using software such as Photoshop<sup>™</sup>. The dimensions of the implant could then be used with a degree of confidence although care would need to be taken when measuring the implant to match the coordinates that the company had used for their dimensions to be of relevance. An example of the stainless steel ball is shown in Fig. 3.

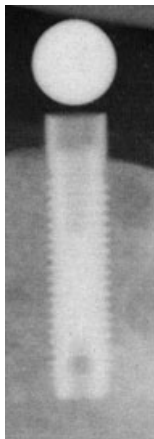

FIG. 3—Implant with stainless steel ball.

A further study comparing antemortem and postmortem images of the same implants would be beneficial in testing the success of radiographic implant recognition to test whether postmortem assaults and different operator images affect the results.

### **Conclusions**

The recognition of dental implants may be beneficial in forensic odontology identification casework or to dental operators in maintaining patients' prosthodontic restorations. This study showed that some implants could be identified from nonstandardized radiographs although the success rate in this study was poor. Success was more attributed to the prior knowledge of each examiner. Use of the current IRS<sup>®</sup> system marginally aided recognition. However, introduction of a new improved system or modifications to the IRS<sup>®</sup> system together with the application of the guide, the use of observations learnt in this study, and the constant expansion of the database could lead to an improved rate of recognition.

### *Acknowledgments*

The authors acknowledge the support of both the Minister for Police in South Australia and the South Australian Police force. The authors wish to thank Dr. Giac Cirillo, in his capacity as an examiner of implant images, Dr. Toby Hughes for his statistical advice, Dr. Peter Hawker for his comparative ideas, the reviewers of this manuscript for their constructive input, and the many dental colleagues who provided images.

### **References**

1. Rothwell BR. Principles of dental identification. *Dent Clin North Am* 2001;45(2):253–70.
2. Wright FD. Dental identification. In: Bowers CM, Bell GL, editors. *Manual of forensic odontology*, 3rd rev. edn. Saratoga Springs: American Society of Forensic Odontology, 1997;9–73.
3. James H, editor. Thai tsunami victim identification overview to date. *J Forensic Odontostomatol* 2005;23:1–18.
4. Valenzuela A, Martin-de las Heras S, Marques T, Exposito N, Bohoyo JM. The application of dental methods of identification to human burn victims in a mass disaster. *Int J Legal Med* 2000;113:236–9.
5. Hutt JM, Ludes B, Kaess B, Tracqui A, Mangin P. Odontological identification of the victims of flight ALIT 5148 air disaster Lyon-Strasbourg 20. *Int J Legal Med* 1995;107:275–9.
6. Solheim T, Lorensen M, Sundnes PK, Bang G, Bremnes L. The "Scandinavian Star" ferry disaster 1990—a challenge to forensic odontology. *Int J Legal Med* 1992;104:339–45.
7. Andersen L, Juhl M, Solheim T, Borrmann H. Odontological identification of fire victims—potentialities and limitations. *Int J Legal Med* 1995;107:229–34.
8. Allen EM, Allen PF. Trauma to an osseointegrated anterior dental implant; a case report. *Dent Traumatol* 2006;22:44–7.
9. Simpson EK, James RA, Eitzen DA, Byard RW. Role of orthopedic implants and bone morphology in the identification of human remains. *J Forensic Sci* 2007;52:442–8.
10. Van Noort R. Titanium: the implant material of today. *J Mater Sci* 1987;22:3801–11.
11. Hermsen KP, Jaeger SS, Jaeger MA. Radiation safety for the NOMAD<sup>™</sup> portable x-ray system in a temporary morgue setting. *J Forensic Sci* 2008;53(4):917–21.
12. Gron P. A geometrical evaluation of image size in dental radiography. *J Dent Res* 1960;39:289–301.
13. Biggerstaff RH, Phillips RJ. A quantitative comparison of paralleling long-cone and bisection-of-angle periapical radiography. *Oral Surg Oral Med Oral Pathol* 1976;62:673–7.
14. Sewerin I. Identification of dental implants on radiographs. *Quintessence Int* 1992;23:611–8.
15. Sahiwal IG, Woody RD, Benson BW, Guillen GE. Macro design morphology of endosseous dental implants. *J Prosthet Dent* 2002;87:543–51.

16. Michelinakis G, Scharrock A, Barclay CW. Identification of dental implants through the use of Implant Recognition Software (IRS). *Int Dent J* 2006;56:203–8.
17. [http://www.businessweek.com/magazine/content/05\\_43/b3956812.htm](http://www.businessweek.com/magazine/content/05_43/b3956812.htm) (accessed October 21, 2008).
18. Reeves P. Visions of normality? Early experiences of radiographic reporting. *Radiography* 2004;10:213–6.
19. <http://www.whichimplant.com/> (accessed October 28, 2008).

Additional information and reprint requests:  
John William Berketa, B.D.S.  
Forensic Odontology Unit  
School of Dentistry  
The University of Adelaide, Frome Road  
Adelaide, SA 5005  
Australia  
E-mail: [john.berketa@adelaide.edu.au](mailto:john.berketa@adelaide.edu.au)