

Rapid detection of sperm: comparison of two methods

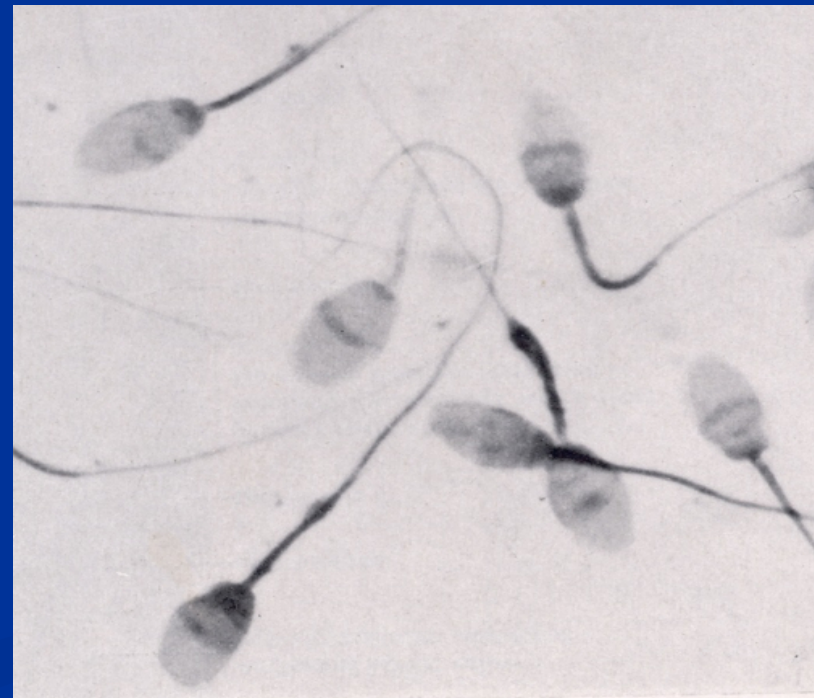By

SARAWUT YEAMSIRI 52312339

Forensic science

Introduction

- Rape case. important evidence is Sperm



Semen composition

Volume 2-6 ml Sperm cell 60 Million /ml

ph= 7.2-8.5

■ seminal plasma

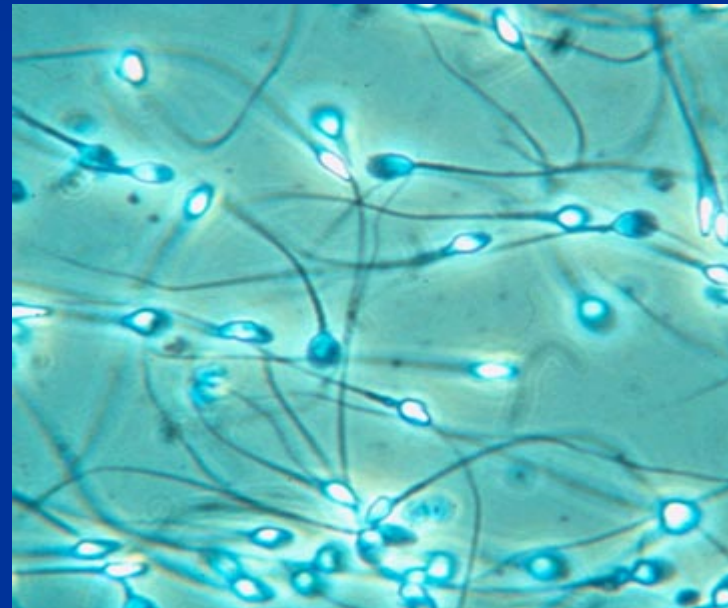
Citric acid Flavin

Acid phosphatase

ABO group Zinc

semenogelin

■ Sperm cell

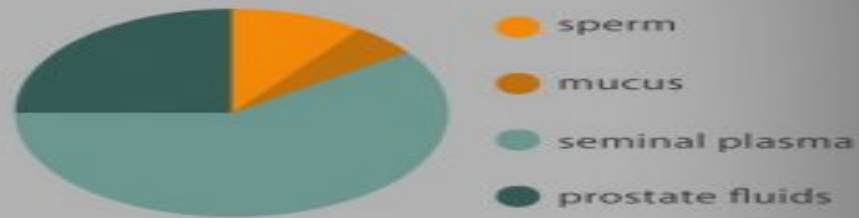

the scoop on
semen

Sperm are **produced** in the male's **testes**



Average **composition** of **semen**



Semen only contain about **10% sperm**, the rest consists of enzymes, vitamin c, calcium, protein, sodium, zinc, citric acid, and fructose sugar

Nutritional Facts	
Serving Size	1 teaspoon (~5 ml)
Servings per Package:	3-5 at any time
Amount per serving	
Calories	20
Total Fat	6 mg
Total Carbohydrates	11 mg
Cholesterol	3 mg
Protein	150 mg
* based on average human male ejaculation	

What **men eat** can affect the **taste** of their sperm




Red meat, dairy products, onions, garlic, and coffee may cause sperm to taste **bitter** and **acidic**



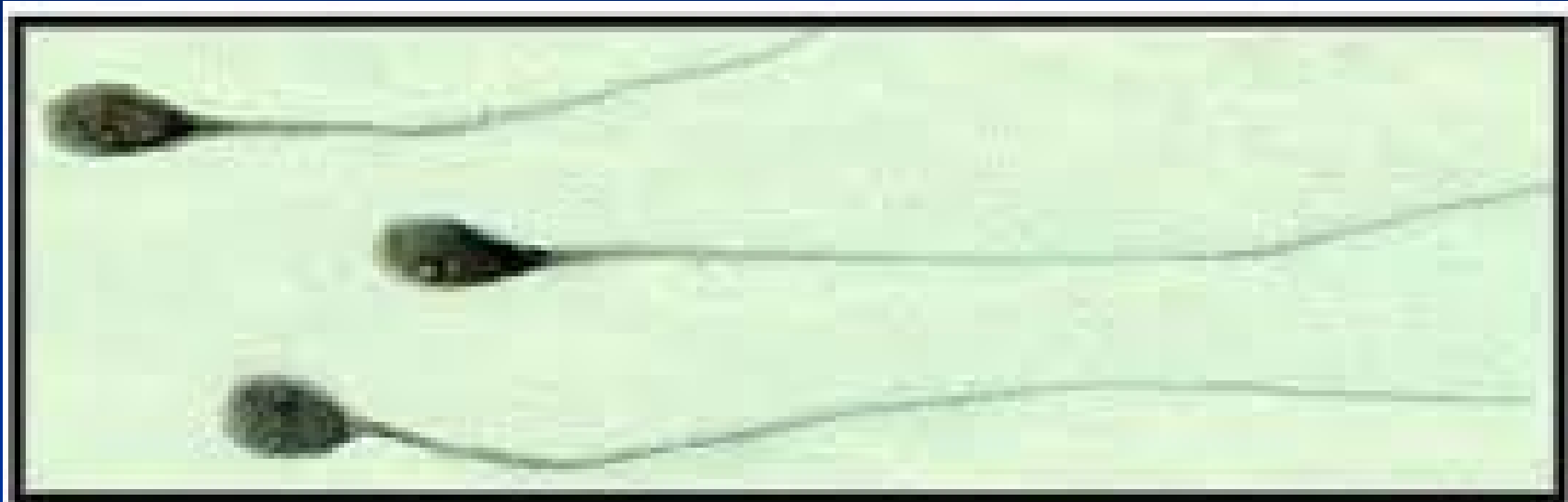
Foods containing natural sugars, such as fruits can make the sperm taste **sweeter**

The **average volume** of semen per ejaculation is **1 teaspoon...**



...each teaspoon of semen can **contain** about **200 to 500 million sperm**

Sperm cell



5 μ m

human sperm in semen (1000X)



 K.P. Armstrong 2001

Laboratory examination

In the case of sex offenses

- Position sperm stain
- Detection of sperm cell + semen
- Biochemical
- DNA typing
- Cell of vaginal (Lugol 's solution)

Detection sperm method

- Acid phosphatase test
- PSA
- Zinc test
- P30 Protein
- (Florence test) Free choline
- Semenogelin
- Precipitin test
- Sperm specific lactate dehydrogenase isozyme
- Leucine aminopeptidase test (LAP test)
- Wet smear
gold standard
- DNA
- H.L.A.
- P.O.M
- Ultraviolet light

Test kid detection



Purpose

- Comparison

Acid phosphatase VS Zinc test

- Sensitivity

- Specificity

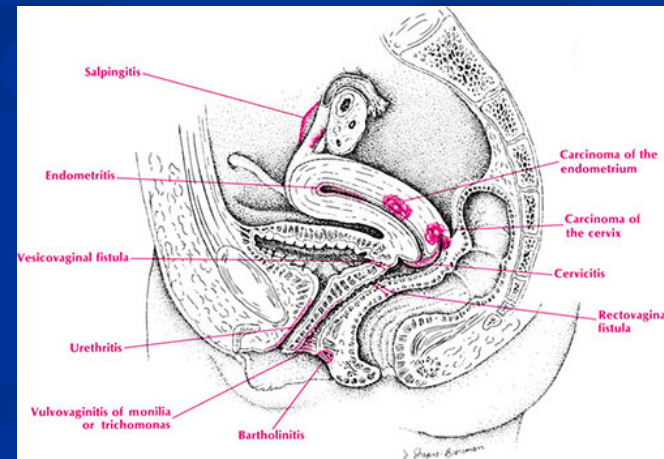
- Predictive negative value

- Predictive positive value

Population studies

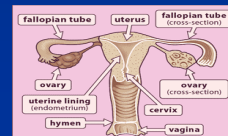
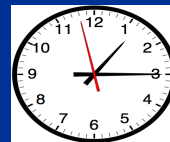
- Women 174 Male Infertility Center
men age 32 years (23–48)
women 30 years (range 21–40).

Collection by vaginal discharge
known last sex intercourse
noted time

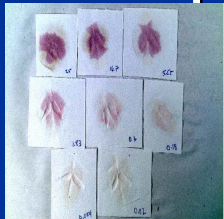


Experimental Diagram

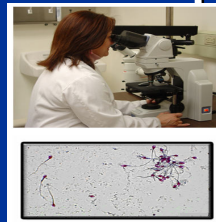
Women 174 Male



Acid phosphatase
174 samples



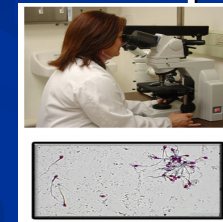
Cytology
174 samples



Zinc test
171 samples



Cytology
171 samples



Student's t test

conclusion

Method

- Rapid test Screening

Acid phosphatase test 174 sample

Zinc test 171 sample

- Confirm test

Cytology : Wet smear

Statistical analysis Student's t test

Acid phosphatase enzyme

- help fertilization

- volume

 - semen 25,000 King-Armstrong U/ml

 - serum 25-50 King-Armstrong U/ml

- working well in acid conditions

- secretions from the prostate gland.

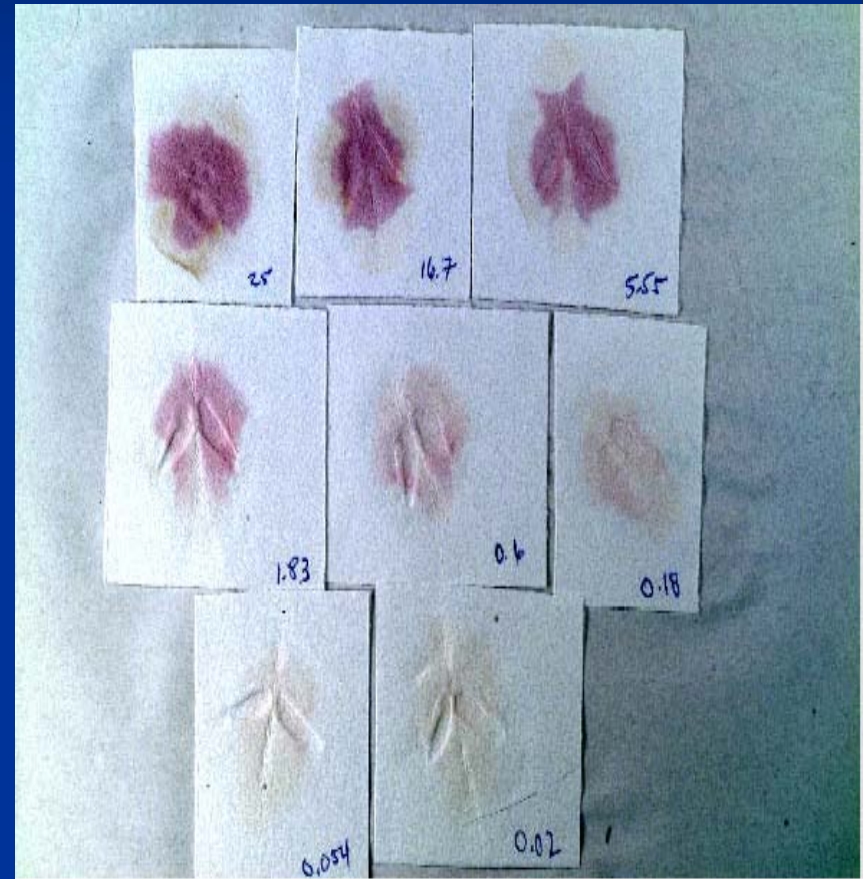
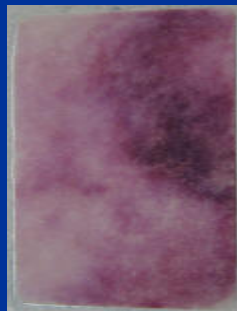- digestion phosphorylcholine in semen

Acid phosphatase test

- Phosphatesmo KM

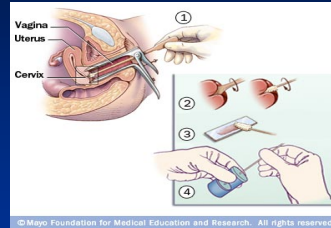
Alpha-naphthyl phosphate
+Brentamine Fast Blue B

POSITIVE : bright purple
within 15 s



Biochemistry

Acid phosphatase test



The swab is applied directly on to the paper strip



Phosphatesmo KM,
Macherey–Nagel, Duren, Germany
Alpha-naphthyl phosphate + Brentamine Fast Blue B



Color reaction :white → violet

Zinc

- Promotion production sperm cell
- Volume

(semen 100-200 mg/L : plasma 1 mg/L)

1 ejaculate loss zinc

5 mg/L



Zinc test

(100-200 mg/L : 1 mg/L in plasma)

Hoof's improved reagent.

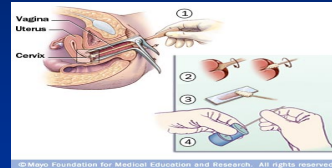
1-(2-Pyridylazo)-2-naphthol

POSITIVE : yellow to pink



Biochemistry


Zinc test



Hoof's improved reagent.
1-(2-Pyridylazo)-2-naphthol



2 drops are applied directly on to the
vaginal sample swab



Color reaction : yellow → pink

Cytology gold standard

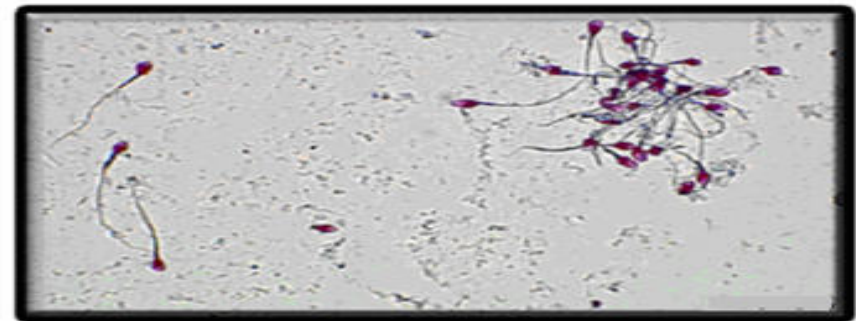
reference test to confirm
the presence of sperm

- Stain

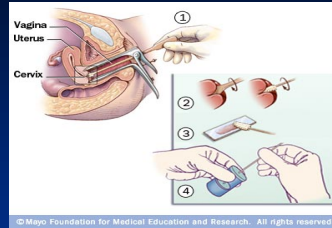
Christmas tree stain

Nuclear fast red

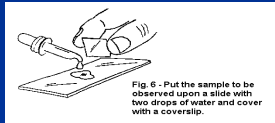
Hematoxylin & Eosin



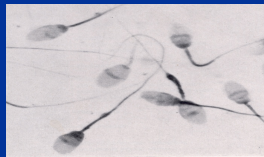
Cytology method



Direct wet smear



Screening sperm by 40X microscopic

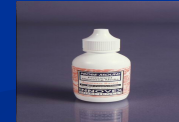

Screening sperm by 40X

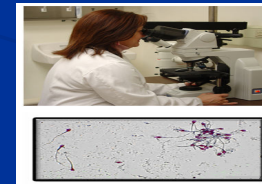
Air dried



fix in alcohol and ether



Stain with nuclear fast red or picroindigocarmine



microscopic

Cytology was the reference test to confirm the presence of sperm in the samples.

Table1

Table 1 Detection of sperm with the acid phosphatase test and cytology

	Cytology - ($n = 111$)	Cytology + ($n = 63$)
Acid phosphatase test - ($n = 110$)	107	3
Acid phosphatase test + ($n = 64$)	4	60

Acid phosphatase test Result

- Sensitivity 95%
- Specificity 96%
- Predictive negative value 98%
- Predictive positive value 93%

Zinc test

Table 2 Detection of sperm with the zinc test and cytology

	Cytology - ($n = 109$)	Cytology + ($n = 62$)
Zinc test - ($n = 70$)	59	11
Zinc test + ($n = 101$)	50	51

Zinc test Result

■ Sensitivity	81%
■ Specificity	54%
■ Predictive negative value	84%
■ Predictive positive value	49%

Table 3

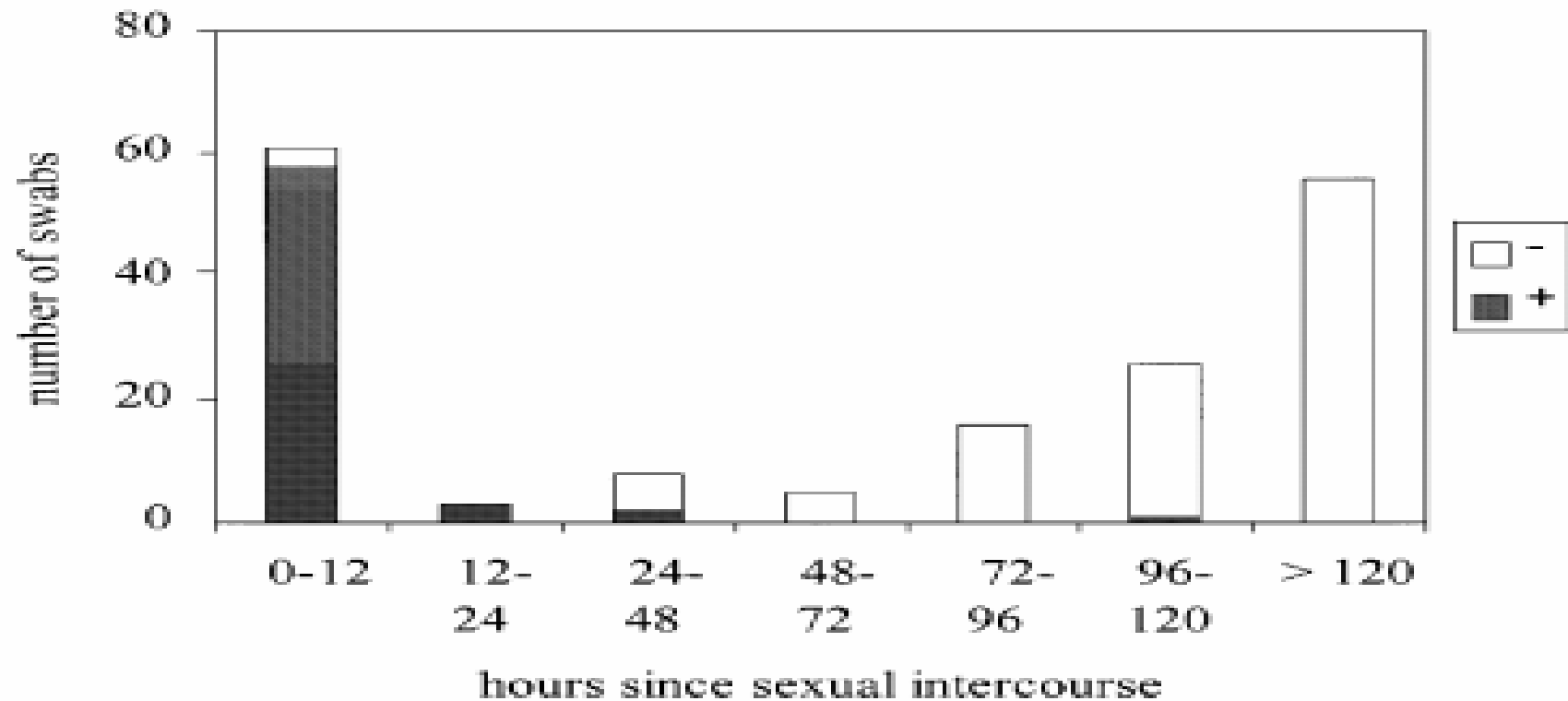


Fig. 1 Internal vaginal swabs. Frequency of positive swabs tested with the acid phosphatase technique according to time since intercourse.

Results

- AP within 24 hr ,a detection rate 96.8%
 within 48 hr ,a detection rate 88.9%
 time limit 106 hr

(false positives) azoospermia or oligospermia
taken early . between 10-36 hr

- Zinc test predictive positive value 49%

Discussion

- AP

 - good sensitivity and specificity

 - screening test

 - (false positives) azoospermia or oligospermia

 - limited duration of enzyme activity 106 hr

- Zinc test

 - detection long period.

 - disappointing in practice

Conclusion

- Acid phosphatase test
 - screening test for routine forensic
 - simple to use, rapid result
- Zinc test
 - unsatisfactory for sperm detection